

Clinical report

Atypical acetabular bone loss in chronic septic total hip arthroplasty loosening

Saran Tantavisut, Aree Tanavalee, Srihatach Ngarmukos, Pongsak Yuktanandana, Vajara Wilairatana, Yongsak Wangroongsub

Department of Orthopedics, Faculty of Medicine, Chulalongkorn University, Bangkok 10330, Thailand

Background: When a periprosthetic infection is diagnosed, the surgical treatment is usually performed as soon as possible to avoid further bone damage or life threatening complications. There is no report on the radiographic change in patients with untreated infected total hip arthroplasty (THA) for several years.

Objective: Report radiographic change in patients with untreated infected THA.

Method: Two patients presented with chronic septic loosening of cemented acetabular fixation after total hip replacement at King Chulalongkorn Memorial Hospital. Both patients had mild hip pain and had been lost for follow-up until the bone destruction became very severe. Serial radiographs after the surgeries were evaluated. The Paprosky's acetabular bone loss classification was used to classify the radiographic findings.

Results: Based on the Paprosky's classification for acetabular bone loss, there were two similar atypical radiographic findings found in both patients. These included pelvic discontinuity from extensive medial acetabular bone loss beyond the Kohler's line, and minimal superior and inferior acetabular bone loss.

Conclusion: These atypical radiographic findings were rarely observed in septic acetabular loosening patients, as infection usually causes patients to present earlier. Following the septic acetabular loosening of THA, surgical procedure should be performed before massive bone damage was demonstrated.

Keywords: Acetabular loosening, atypical, cemented fixation, radiographic finding, septic, total hip replacement

When a periprosthetic infection is diagnosed, the surgical treatment is usually performed as soon as possible to avoid further bone damage or life threatening complications [1, 2]. Clinical symptoms of periprosthetic infection may present in a wide range of pain from mild to severe, which may relate to improper treatment.

In prolonged infected total hip arthroplasty (THA), serial radiographs usually demonstrate loosening of components with increase in bone destruction. However, it is rare that patients could tolerate chronic periprosthetic infection until severe acetabular bone-loss developed. There is no report on the radiographic change in patients with untreated infected THA for several years.

In this study, we report two patients having atypical cemented acetabular loosening following chronic septic THA and describe common radiographic patterns of acetabular bone destruction found in both patients.

Cases report

Two patients presented with prolonged periprosthetic infection after THA with mild pain and ability to continue the activity of daily living at King Chulalongkorn Memorial Hospital. Both patients were diagnosed with periprosthetic infection by an orthopedic surgeon. They both refused surgical management until they developed severe pain.

Serial radiographs after the surgeries until the date patients presented to our institution were evaluated. The Paprosky's acetabular bone loss classification [3] was used to classify the radiographic findings. Progression and pattern of acetabular bone loss were evaluated corresponding to the time of diagnosis.

Correspondence to: Assoc. Prof. Aree Tanavalee, MD, Department of Orthopedics, Faculty of Medicine, Chulalongkorn University, Bangkok 10330, Thailand. E-mail: areetang@ortho.chula.com

Case 1

A 60-year-old Asian male underwent staged-bilateral cemented THA due to bilateral avascular necrosis of the femoral head. At 6-month follow-up, he had no pain and had much improved function. At one year, he reported mild right hip pain, which had been present for three months. Erythrocyte sedimentation rate (ESR) and C-reactive protein (CRP) were elevated at 70 mm/hour and 45 mg/L at that time.

Figure 1 shows radiographs of the patient. We note one-mm radiolucent line in all zones of acetabulum according to DeLee and Charnley [4] (**A**). Infected right THA was the provisional diagnosis and surgery with two-staged revision THA was discussed. However, he refused any hip aspiration or surgery. Thus, only intravenous and oral antibiotic was administered for six weeks with clinical improvement noted. He was lost for follow-up until four years after surgery. He had increasing right hip pain with

radiographic evidence of migration of the acetabular component (**B**) and increasing acetabular bone destruction. Again, he insisted to continue periodic oral antibiotic suppression. After another year, he came back with uncontrolled right hip pain and profound loss of daily function. The radiographs showed further medial wall destruction with protrusion of the cup beyond the medial acetabular wall (**C**). Although the medial bone loss became a pelvic discontinuity, the superior or inferior acetabular bone was minimally destroyed. The primary surgical treatment was implant removal and extensive debridement. As his physical health was much deteriorated at the recent admission, and the three-month monitoring of ESR and CRP levels were still higher than normal range after implant removal, resection arthroplasty was finally chosen, and no reimplantation was performed. The overall time that this patient had periprosthetic THA infection with inadequate treatment was a minimum of four years.

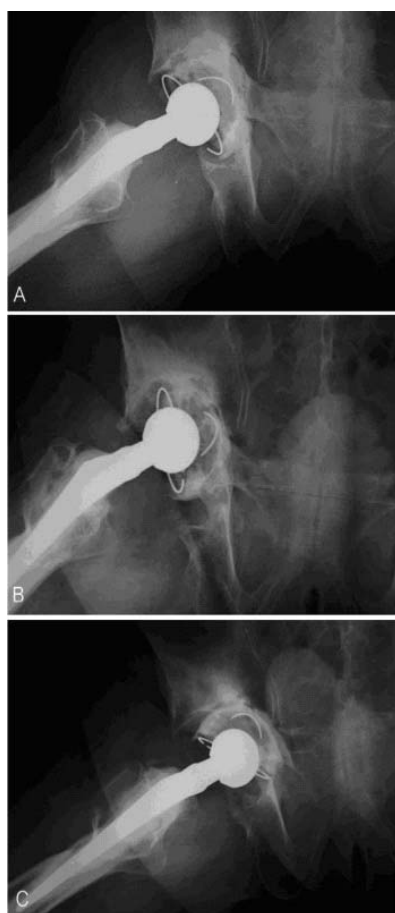


Figure 1. **A:** Radiograph at one year after index operation. There was a complete <1mm radiolucency line in all zones of right acetabulum. **B:** Radiograph at four years after index operation. There was migration and medial protrusion beyond the ilio-ischial line of the acetabular component. **C:** Radiograph at five years after index operation. There was a further medial protrusion and more horizontal orientation of acetabular component.

Case 2

A 65 year-old Asian monk having late stage of avascular necrosis of both hips underwent staged bilateral cement THA. He had done well for six years. At eight-year follow-up, he presented with increasing left hip pain for two years and intermittent drainage from the incision scar for a few weeks. The ESR and CRP were elevated at 60 mm/hour and 35 mg/L. No hip aspiration was performed due to patient's refusal.

Figure 2 shows radiographs of the patient. We note a complete two-mm radiolucency line in all acetabular zones [5-7] (**A**). He was diagnosed as having septic acetabular loosening and was recommended to undergo surgery. He refused surgery and was lost for follow-up for other two years. Then, he came back with increasing left hip pain and impaired daily function. The radiograph demonstrated migration of the acetabular component towards the medial wall (**B**). However, he still refused any surgical treatment. One year later (11 years after surgery), he presented again with intolerable hip pain which caused him to accept the surgical treatment. The latest

radiograph demonstrated pelvic discontinuity through the acetabular medial wall and minimal destruction of the superior and inferior acetabular bone (**C**). Three months after implant removal and extensive debridement, the hip was painless, but the ESR and CRP levels were still slightly higher than normal values. He declined to undergo further surgery. The overall time that this patient had periprosthetic THA infection with inadequate treatment was approximately three years.

Discussion

Both cases demonstrated two similar atypical radiographic findings. These included 1) migration of the cup towards the medial wall with no reactive bone surrounding the cup resulting in pelvic discontinuity, 2) minimal bone destruction in both superior and inferior acetabulum. In fact, these two findings are not common in aseptic loosening of cemented acetabular component, or septic loosening. Patients usually have surgical management before the condition develops at such a late stage.

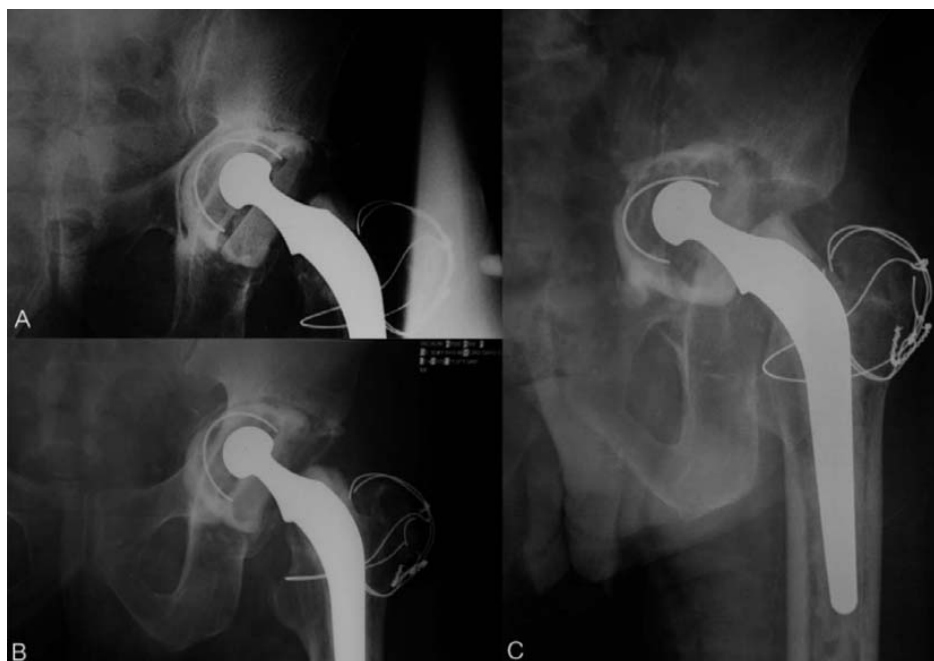

Figure 2. **A:** Radiograph at eight years after index operation demonstrates complete ≥ 2 mm radiolucency line in all zones of acetabulum. **B:** Radiograph at 10 years after index operation. There was a medial protrusion of both acetabular component and cemented mantle with eccentric polyethylene wear. Although the pelvic discontinuity had developed, the superior and inferior acetabular bone losses were much less severe. **C:** Radiograph at 11 years after index operation demonstrates extensive medial protrusion of acetabular wall into pelvic cavity with minimal superior bone-loss. When the infection has been presented for such a prolonged duration, the medial acetabular bone-loss became massive.

In aseptic cemented acetabular loosening, the acetabular bone destruction is proportional among the superior, the inferior, and the medial acetabulum, which creates an enlarged cavitory defect. The slow process of loosening allow reactive bone formation along the medial acetabular wall, which results in maintaining the eroded medial wall to continue a contained cavitory defect, even though the loosening has been left for a long time.

Radiographic findings in both patients had different patterns of acetabular bone destruction from aseptic loosening. The severe medial acetabular wall damage with minimally upward cup migration implied that a certain condition caused bone destruction in the direction of resultant force of the hip joint under loading, while the quality of bone or the process of bone metabolism in this area was not normal [8-10]. The bone around the acetabulum could not remodel or repair itself to accommodate the repetitive load. Thus, migration in the direction for resultant force occurred and caused protrusion of the medial wall without reactive bone formation.

In conclusion, when loosening of cemented acetabular component is presented with two radiographic findings: 1) migration of the cup towards the medial wall without reactive bone surrounding the cup resulting in pelvic discontinuity and 2) minimal bone destruction in both superior and inferior acetabulum, abnormal bone conditions such as infection or rapid bone destruction should be suspected. Untreated sepsis of a cemented THA leads to progressive protrusion and, ultimately, pelvic discontinuity. Patients should be warned that postponing surgical treatment of cemented THA infection seems to decrease the likelihood of successful reimplantation.

The authors have no conflict of interest to report.

References

1. Salvati EA, Gonzalez Della Valle A, Masri BA, Duncan CP. The infected total hip arthroplasty. *Instr Course Lect.* 2003; 52:223-45.
2. Tsukayama DT, Estrada R, Gustilo RB: infection after total hip arthroplasty. A study of the treatment of one hundred and six infections. *J Bone Joint Surg (Am).* 1996; 78A:512-23.
3. Paprosky WG, Burnett RS: Assessment and classification of bone stock deficiency in revision total hip arthroplasty. *Am J Orthop.* 2002; 31:459-64.
4. DeLee JG, Charnley J. Radiologic demarcation of cemented sockets in total hip replacement. *Clin orthop.* 1976; 121:20-32.
5. Hodgkinson JP, Shelley P, Wroblewski BM. The correlation between the roentgenographic appearance and operative findings at the bone-cement junction of the socket in Charnley low friction arthroplasties. *Clin Orthop.* 1988; 228:105-9.
6. Tehranzadeh J, Schneider R, Freiburger RH. Radiological evaluation of painful total hip replacement. *Radiology.* 1981; 141:355-62.
7. Carlsson AS, Gentz CF. Radiographic versus clinical loosening of the acetabular component in noninfected total hip arthroplasty. *Clin Orthop.* 1984; 185:145-50.
8. Crowninshield RP, Brand RA, Pederson DR. A stress analysis of acetabular reconstruction in protrusion acetabuli. *J Bone Joint Surg Am.* 1983; 65:495-9.
9. Vasu R, Carter DR, Harris WH. Stress distributions in the acetabular region-I before and after total joint replacement. *J Biomech.* 1982; 15:155-64.
10. Wroblewski BM. Direction and rate of socket wear in Charnley low friction arthroplasty. *J Bone Joint Surg Br.* 1985; 67B:757-61.