

# Anatomical Landmark of Descending Genicular Artery for Minimidvastus Approach of the Knee

Satit Thiengwittayaporn MD\*,  
Somkhuan Paradeerujira MD\*, Aree Tanavalee MD\*\*

\* Department of Orthopaedics Surgery, Bangkok Metropolitan Administration Medical College and Vajira Hospital, Bangkok, Thailand

\*\* Department of Orthopaedics, Faculty of Medicine, Chulalongkorn University, Bangkok, Thailand

---

**Objective:** To determine the anatomical course of descending genicular artery and to identify a safety zone for minimidvastus approach.

**Material and Method:** Forty-eight knees from twenty-four fresh cadavers were dissected to identify the descending genicular artery, and to measure the distance between such artery and superomedial pole of the patella as well as the entry angle of such artery to the perpendicular line of the vertical axis of the patella.

**Results:** The average distance between the descending genicular artery and superomedial pole of the patella was 8.1 millimeters (0-19 millimeters) and the average entry angle of such artery to the patella was 44.5 degrees (32-60 degrees).

**Conclusion:** The safety zone for splitting the vastus medialis in minimidvastus approach was the angle of not more than 32 degrees from the perpendicular line of the vertical axis of the patella. However, there is no safety zone in term of the distance between the dissected vastus medialis and the superomedial border of the patella.

**Keywords:** Descending genicular artery, Minimidvastus approach, Total knee arthroplasty

**J Med Assoc Thai 2009; 92 (Suppl 6): S59-62**

**Full text. e-Journal:** <http://www.mat.or.th/journal>

---

Various conventional surgical approaches for Total Knee Arthroplasty (TKA) have been described such as medial parapatellar, subvastus, midvastus, and lateral parapatellar<sup>(1-5)</sup>. Medial parapatellar approach is the standard and adequate exposure<sup>(6)</sup>, however, the disadvantage of this approach include disturbing blood flow to the patella and patellar tracking<sup>(7,8)</sup>. Recently, the minimally invasive surgery (MIS) has been introduced to decrease soft tissue trauma, post-operative pain, hospital stays, and increase functional recovery<sup>(9,10)</sup>. There are 4 MIS-TKA approaches: limited parapatellar, quadriceps-sparing, minisubvastus, and minimidvastus<sup>(9)</sup>. The minimidvastus approach has been shown an effective means of entering the knee joint for MIS-TKA. This approach splits the vastus

medialis obliquus (VMO) proximally at the superomedial border of the patella, and the distal portion of arthro-tomy is identical to the medial parapatellar approach. Dissection VMO proximally from superomedial pole of the patella may damage the descending genicular artery, which is one of the most important arteries supplying to the patella<sup>(11,12)</sup>.

The purposes of this study were determining the anatomical course of descending genicular artery and identifying a safety zone for minimidvastus approach.

## Material and Method

Forty-eight knees of 24 fresh cadavers were dissected to identify the descending genicular artery, and to measure the distance between the artery and superomedial border of patella and also the entry angle of the artery to the patella. The femoral artery of each cadaver were identified and then infused with the colored latex. The knee was opened layer by layer. The

---

Correspondence to: Thiengwittayaporn S, Department of Orthopaedics Surgery, Bangkok Metropolitan Administration Medical College and Vajira Hospital, 681 Samsaen Rd, Bangkok 10300, Thailand. Phone: 0-2244-3376, Fax: 0-2243-6106. E-mail: satitthh@hotmail.com

descending genicular artery and its branches were isolated from the point of origin and were dissected to the patella (Fig. 1). The center of patella was identified by the bisect line of the patella in vertical and horizontal plane. Then, the bisect line of patella tendon to center of patella was made to be used as reference of the vertical axis. The entry angle to the patella, the angle between the perpendicular line of the vertical axis and the line of the descending genicular artery, was measured (Fig. 2). The distance between the artery and superomedial border of patella was also measured (Fig. 3).

### Statistical analysis

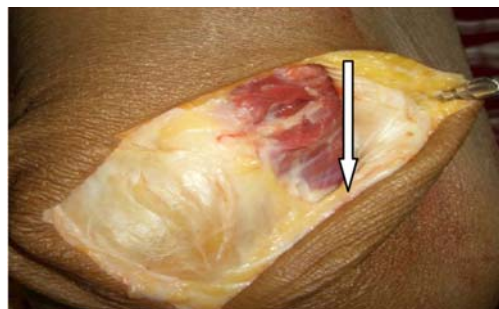All data were combined using descriptive statistics. Continuous variable were calculated as the mean and range.

### Results

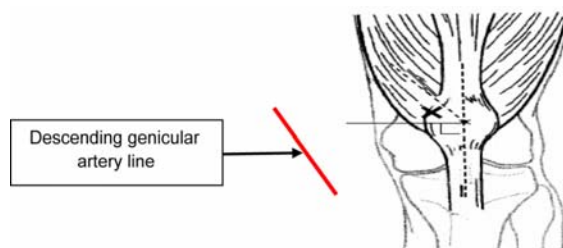
The mean age of the cadavers was 28.3 years (18-44 years). All specimens were from the male. The mean entry angle was 44.5 degrees (32-60 degrees). The mean distance between the descending genicular artery and superomedial border of the patella was 8.1 mm (0-19 mm) (Table 1).

### Discussion

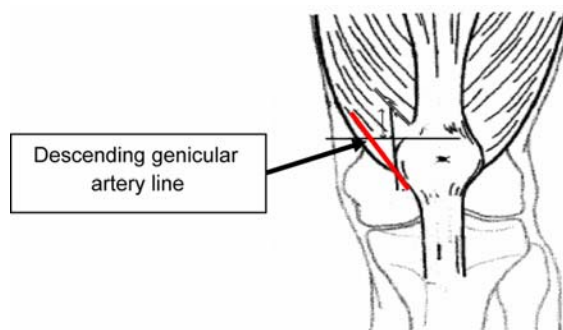
The medial parapatellar has been the most frequently used and the satisfied approach for TKA. Although it was an appropriate approach for TKA, it might disrupt the medial patellar blood flow and the extensor mechanism<sup>(11,12)</sup>. The subvastus is a quadriceps-sparing approach, which releases the vastus medialis along an intramuscular plane and does not violate the extensor mechanism. However, it might be the limited exposure in the obese and the prominent vastus medialis patients<sup>(13)</sup>. The midvastus approach made a compromise between the increasing of exposure (medial parapatellar) and the minimizing of the disruption of the extensor mechanism (subvastus



**Fig. 1** Dissected descending genicular artery (arrow) of right fresh cadaver knee



**Fig. 2** The entry angle to the patella (X)



**Fig. 3** The distance between the artery and superomedial border of patella

**Table 1.** The mean and range of the patient's age, entry angle to the patella and the distance between the artery and superomedial border of patella from 48 cadaveric knees

Variable	Mean	Range
Age (years)	28.3	18-44
Entry angle to the patella (degrees)	44.5	32-60
Distance between the artery and superomedial border of patella (millimeters)	8.1	0-19

approach)<sup>(9,13)</sup>. Nowadays, the minimally invasive surgery (MIS) has been developed to achieve the results of TKA with a smaller incision, and reduced trauma to the soft tissue and the extensor mechanism. The minimidvastus approach became popular because it preserved the extensor mechanism and the patellar blood flow comparing with the medial parapatellar approach<sup>(3,9)</sup>. In other reports, the authors had suggested that the improvement in early post-operative of the quadriceps strength was as rapidly as the functional recovery<sup>(13)</sup>.

In the minimidvastus approach<sup>(9)</sup>, a limited anterior midline skin incision was made to expose the board insertion of the vastus medialis. Then, the vastus medialis was divided by the knee in full flexion, beginning at the superomedial corner of the patella and extending 2-3 cm proximally. This incision may damage the descending genicular artery, one of the major contributors to the patellar blood supply. The disruption of the descending genicular artery might increase the blood loss and the patellar-related complications such as a vascular necrosis and patellar fracture<sup>(14)</sup>.

Basarir and associates<sup>(14)</sup> investigated the course of the descending genicular artery in 30 knees from 15 formaldehyde-fixed human cadavers. They found that the average entry angle was 33 degrees (20-40 degrees) from the vertical axis (average 66 degrees, the range of 50-70 degrees from the perpendicular line of the vertical axis) and the average distance between the descending genicular artery and superomedial pole of the patella was 13.5 mm (6.9-22.4 mm). Their conclusion was that the safety zone for splitting the vastus medialis had the range of 15 mm from the upper pole of patella and not more than 50 degrees from the perpendicular line to the vertical axis of the patella.

In this study, the results were different to the study of Basarir and associates. We found that the average entry angle was 44.5 degrees (32-60 degrees) from the perpendicular line of the vertical axis of the patella and the average distance between the descending genicular artery and superomedial border of the patella was 8.1 mm. (0-19 mm). The reason of different results may be the using of fresh cadavers, which is more closely with the natural knee. Since we found a subject that the descending genicular artery was close to the superomedial border of the patella (0 mm), it might not have the safety zone in term of the distance.

A weakness of the current study is that all of the cadavers are the male gender. Additionally, the

prospective studies are needed to further investigation in the female gender which may be the different course of the descending genicular artery.

## Conclusion

The safety zone for splitting the vastus medialis in minimidvastus approach was not more than 32 degrees from the perpendicular line of the vertical axis. However, there is no safety zone in term of distance between the dissected vastus medialis and the superomedial border of the patella. Therefore, the minimidvastus approach should be extremely careful to avoid the damage of the descending genicular artery.

## References

1. Hofmann AA, Plaster RL, Murdock LE. Subvastus (Southern) approach for primary total knee arthroplasty. *Clin Orthop Relat Res* 1991; (269): 70-7.
2. Scuderi GR, Insall JN. Total knee arthroplasty. Current clinical perspectives. *Clin Orthop Relat Res* 1992; (276): 26-32.
3. Engh GA, Holt BT, Parks NL. A midvastus muscle-splitting approach for total knee arthroplasty. *J Arthroplasty* 1997; 12: 322-31.
4. Dalury DF, Jiranek WA. A comparison of the midvastus and paramedian approaches for total knee arthroplasty. *J Arthroplasty* 1999; 14: 33-7.
5. Parentis MA, Rumi MN, Deol GS, Kothari M, Parrish WM, Pellegrini VD Jr. A comparison of the vastus splitting and median parapatellar approaches in total knee arthroplasty. *Clin Orthop Relat Res* 1999; (367): 107-16.
6. Bonutti PM, Mont MA, McMahan M, Ragland PS, Kester M. Minimally invasive total knee arthroplasty. *J Bone Joint Surg Am* 2004; 86-A (Suppl 2): 26-32.
7. Clayton ML, Thirupathi R. Patellar complications after total condylar arthroplasty. *Clin Orthop Relat Res* 1982; (170): 152-5.
8. Kayler DE, Lyttle D. Surgical interruption of patellar blood supply by total knee arthroplasty. *Clin Orthop Relat Res* 1988; (229): 221-7.
9. Scuderi GR. Minimally invasive total knee arthroplasty: surgical technique. *Am J Orthop* 2006; 35 (7 Suppl): 7-11.
10. Tanavalee A, Thiengwittayaporn S, Ngarmukos S. Rapid ambulation and range of motion after minimally invasive total knee arthroplasty. *J Med Assoc Thai* 2004; 87(Suppl 2): S195-201.

11. Brick GW, Scott RD. Blood supply to the patella. Significance in total knee arthroplasty. J Arthroplasty 1989; 4(Suppl): S75-9.
12. Bonutti PM, Miller BG, Cremens MJ. Intraosseous patellar blood supply after medial parapatellar arthrotomy. Clin Orthop Relat Res 1998; (352): 202-14.
13. Scuderi GR, Tenholder M, Capecci C. Surgical approaches in mini-incision total knee arthroplasty. Clin Orthop Relat Res 2004; (429): 61-7.
14. Basarir K, Erdemli B, Tuccar E, Esmer AF. Safe zone for the descending genicular artery in the midvastus approach to the knee. Clin Orthop Relat Res 2006; 451: 96-100.

---

### ลักษณะทางกายวิภาคของหลอดเลือดที่มาเลี้ยงเข่าเหนือกระดูกสะบ้าต้นในสำหรับการผ่าตัดเข้าข้อเข่าโดยผ่านกล้ามเนื้อเหนือเข่า

สาธิต เทียงวิทยพร, สมควร ภารศิริจิรา, อารี ตनावลี

**วัตถุประสงค์:** เพื่อศึกษาหาตำแหน่งของหลอดเลือดที่มาเลี้ยงเข่าเหนือกระดูกสะบ้าต้นใน (descending genicular artery) และบริเวณที่ปลอดภัยในการผ่าตัดเข้าข้อเข่าโดยผ่านกล้ามเนื้อเหนือเข่า (minimidvastus approach)

**วัสดุและวิธีการ:** ทำการศึกษาหลอดเลือดที่มาเลี้ยงเข่าเหนือกระดูกสะบ้าต้นในจำนวน 48 เข่า จากศพจำนวน 24 ศพ โดยวัดระยะห่างจากขอบบนของกระดูกสะบ้าต้นในถึงหลอดเลือดที่มาเลี้ยงเข่าเหนือกระดูกสะบ้าต้นในและมุมจากหลอดเลือดดังกล่าวถึงเส้นตั้งฉากจากแนวตั้งของเข่า

**ผลการศึกษา:** ระยะห่างจากขอบบนของกระดูกสะบ้าต้นในถึงหลอดเลือดที่มาเลี้ยงเข่าเหนือกระดูกสะบ้าต้นในเฉลี่ย 8.1 มิลลิเมตร (0-19 มิลลิเมตร) และมุมจากหลอดเลือดดังกล่าวถึงเส้นตั้งฉากจากแนวตั้งของเข่าเฉลี่ย 44.5 องศา (32-60 องศา)

**สรุป:** ตำแหน่งที่ปลอดภัยจากการผ่าตัดเข้าข้อเข่าโดยวิธีเข้าสู่กล้ามเนื้อเหนือเข่า คือแนวของการเข้าสู่ข้อเข่าที่มีค่าเฉลี่ยของมุมจากหลอดเลือดที่มาเลี้ยงเข่าเหนือกระดูกสะบ้าต้นในถึงเส้นตั้งฉากจากแนวตั้งของเข่าไม่เกิน 32 องศา และไม่มีตำแหน่งที่ปลอดภัยในแง่ของระยะทางเหนือขอบบนต้นในของกระดูกสะบ้า

---